

An intra-articular knee cyst in a 2-year-old associated with an aberrant anterior cruciate ligament

Todd C. Battaglia · Aaron M. Freilich ·
David R. Diduch

Received: 19 December 2005 / Accepted: 24 January 2006
© Springer-Verlag 2006

1
2 **Abstract** Intra-articular ganglia of the knee occur
3 infrequently, with an overall incidence estimated to be
4 from 0.2 to 1.9%. To date, the youngest patient
5 reported with an intra-articular ganglion was an ado-
6 lescent. In this paper, we describe a 2-year-old patient
7 with a massive intra-articular knee cyst and an aberrant
8 anterior cruciate ligament (ACL) origin. The cyst was
9 successfully treated with arthroscopic debridement.
10 Proposed pathology and treatment recommendations
11 for intra-articular cysts are reviewed.

12 **Keywords** Ganglion cysts · Anterior cruciate
13 ligament · Knee · Pediatrics · Child

Introduction

Intra-articular ganglia of the knee occur infrequently,
with an overall incidence estimated to be from 0.2 to
1.9%, but are documented in the orthopaedic litera-
ture [3, 8, 10]. The incidence in children has not been
studied. To date, the youngest patient reported with
an intra-articular ganglion was a 12-year-old adoles-
cent [9]. In this paper, we describe a 2-year-old patient
with a massive intra-articular knee cyst and an aber-
rant anterior cruciate ligament (ACL) origin. To the
best of our knowledge, this association has not been
previously reported.

Case report

C.S. is a 2-year, 3-month-old male who presented to his
local orthopaedist with a 1- month history of limp and
low-grade left knee pain. Clinic notes retrieved from
that visit report mild, diffuse swelling about the knee
but no other abnormalities, such as warmth, ligamen-
tous instability, or loss of motion. After the limp failed
to improve during an additional 2-month period of
observation, an MRI was obtained and demonstrated a
fluid-filled mass in the knee joint. The patient was
subsequently referred to our clinic.

At our institution, the patient and his family denied
any history of trauma or infection. Past medical history
was benign. No other joint symptoms were reported.
On examination, marked left quadriceps atrophy was
evident. There was mild effusion without skin abnor-
mality. The knee was stable to ligamentous stress in all
directions, but active and passive range of motion
demonstrated a 25° extension deficit. Plain radiographs

Investigation was performed at the University of Virginia Health
Science Center, Charlottesville, VA, USA

T. C. Battaglia (✉)
Department of Orthopaedic Surgery,
New England Baptist Hospital, 125 Parker Hill Avenue,
Boston, MA 02120, USA
e-mail: tcbattags@yahoo.com

A. M. Freilich · D. R. Diduch
Department of Orthopaedic Surgery, University of Virginia
Health System, 400 Ray C. Hunt Drive, Box 800159,
Charlottesville, VA 22908-0159, USA

A. M. Freilich
e-mail: amf7z@virginia.edu

D. R. Diduch
e-mail: drd5c@virginia.edu

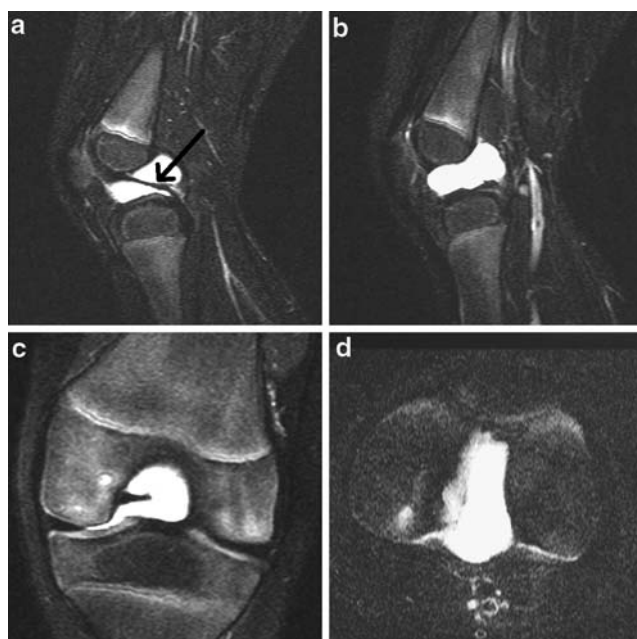


Fig. 1 Pre-operative T2-weighted sagittal (a) and (b), coronal (c), and axial (d) MRI images demonstrating extensive intra-articular cystic structure. The cyst envelops the PCL *arrow* in (a). The ACL was not visualized on MRI

45 were unremarkable. The MRI previously obtained was
46 reviewed and showed a homogenous, intra-articular,
47 high-(T2)-intensity, cystic structure intimately involved
48 with and surrounding the posterior cruciate ligament
49 (PCL) (Fig. 1). Radiographic diagnosis was ganglion
50 cyst. The ACL was not visualized.

51 Arthroscopy with cyst removal was recommended.
52 Examination under anesthesia confirmed loss of
53 extension. Intra-operatively, a large intra-articular mass
54 was found with an appearance consistent with ganglion
55 cyst. The mass occupied the entire intercondylar notch,
56 extended into the medial and lateral compartments,
57 and was adherent to the articular cartilage of both the
58 medial and lateral femoral condyles (Fig. 2). The cru-
59 ciate ligaments could not be seen. The cyst was noted to
60 impinge during knee extension. In addition, an incom-
61 plete, non-Wrisberg discoid lateral meniscus was seen.
62 Careful inspection and dissection determined that the
63 cyst did not appear to involve or emanate from either
64 meniscus. Both menisci were without tears and the
65 discoid meniscus was not débrided.

66 Upon careful arthroscopic excision of the anterior
67 cyst wall, a yellow gelatinous material was released.
68 The remainder of the cyst, which appeared to be inti-
69 mately associated with the ACL, was débrided and the
70 anterior and posterior cruciates inspected (Fig. 3). No
71 pathology specimen was sent. The PCL was intact and
72 in normal position. The ACL position, however, was
73 abnormal, with a femoral origin more distal and ante-

rior on the lateral condyle than expected, near the
74 antero-inferior articular edge of the condyle. The lig-
75 ament became appropriately taut under stress without
76 excessive anterior tibial translation. Full knee exten-
77 sion was obtained after cyst removal.

78
79 Post operatively, the patient was discharged to home
80 and recovered uneventfully. At 10-day follow-up, he
81 was walking with minimal antalgic limp and had
82 already resumed running at home. Active extension
83 lacked only 5°. At 9-month follow-up, the patient had
84 recovered full motion and strength, resumed full
85 activity, and was discharged from our care. The parents
86 were informed that this case would be submitted for
87 publication.

Discussion

88
89 In this study, we present the diagnosis and successful
90 treatment of an intra-articular knee ganglion in the
91 youngest reported patient to date. Although the ear-
92 liest report of a ganglion from the ACL was presented
93 in 1924 [4], it was not until the past 20 years that
94 reports on such intra-articular masses have become
95 common. In the largest report on intra-articular knee
96 ganglia, 85 cysts were found during a series of nearly
97 8,000 arthroscopies [10]. In another series of 6,500 knee
98 arthroscopies, Brown [2] reported a 0.58% incidence of
99 intra-articular ganglia. Radiographic studies have
100 confirmed this, with two large MRI series reporting
101 intra-articular ganglion rates of 1.8% (76/4,221) [1] and
102 1.3% (23/1,767) [3]. In all series, the majority of ganglia
103 arose from one of the cruciate ligaments, with the ACL
104 the most common site of origin. Sporadic descriptions
105 of intra-articular ganglia arising from the infra-patellar
106 fat pad, the menisci, the popliteus tendon, or from

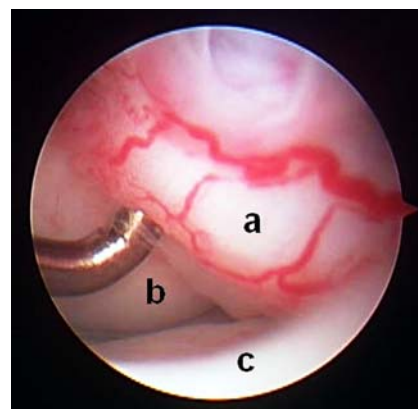


Fig. 2 Arthroscopic image taken from the anterolateral portal showing large cyst (a) filling the femoral notch and partially obscuring the medial femoral condyle (b) and tibial plateau (c)

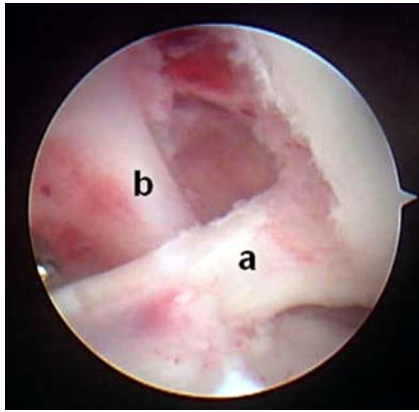


Fig. 3 After complete cyst débridement, the ACL (a) and PCL (b) are seen. Note the horizontal course and aberrant location of the ACL, inserting in a distal and anterior location on the lateral femoral condyle

107 extension of subchondral cysts have also appeared
108 [2, 3, 6, 8, 10, 11]. Most reported cases have been
109 incidental findings [10]. When symptomatic, knee pain,
110 especially with extreme flexion or extension, is the
111 most common complaint. Swelling, popping, or sub-
112 jective “giving way” have also been reported [1, 6].
113 Only occasionally do these ganglia cause mechanical
114 symptoms [7, 13, 14].

115 Intra-articular knee ganglia are most common in pa-
116 tients aged from approximately 20–45 years old [6], al-
117 though a thorough literature search found isolated
118 reports of such cysts in an 18-year-old [5], 15-year-old
119 [14], 13-year-old [8], and 12-year-old [9]. The patient
120 described here is the first infant or child described with
121 an intra-articular knee cyst. Most interesting, however,
122 is the association with an abnormal cruciate ligament
123 position. Numerous theories of cyst development have
124 been proposed, including theories based on (1) mucin-
125 ous degeneration of connective tissue, (2) synovial her-
126 niation, (3) congenitally displaced synovial tissue, and
127 (4) trauma [1, 5, 7, 9, 10, 14]. In our patient, it is possible
128 that the ganglion cyst and abnormal ACL position are
129 end results of the same underlying pathologic connec-
130 tive tissue process. More likely, however, we propose
131 that the abnormal cruciate position developed due to
132 mass effect from the cyst. Ganglia are capable of creat-
133 ing significant anatomic pressures, even so far as bony
134 erosion into the femoral condyles has been described [5,
135 7, 11, 13, 14]. Although we could find no other reports of
136 ganglia specifically altering ligament development, we
137 believe that this large cyst, centered in the femoral notch
138 of a very young patient, exerted a deforming force
139 during the ACL development and femoral growth,
140 resulting in a more anterior and distal insertion site.

141 Arthroscopy with cyst removal is recommended for
142 all patients with symptomatic ganglia and nearly

always results in complete resolution [6, 10, 14]. Unlike
extra-articular ganglia, recurrences are exceedingly
rare after arthroscopic drainage and débridement of
intra-articular cysts [6, 8]. In the largest reported series,
no recurrences were reported in 85 of 85 patients [10]
and 15 of 15 patients [12] and good or excellent clinical
outcomes were reported in 36 of 38 patients [2] after
arthroscopic débridement. In our patient, full motion
and normal gait were rapidly achieved after cyst exci-
sion and were maintained through final follow-up.
Further follow-up will be necessary to determine
whether the anomalous ACL position will cause any
long-term effects.

References

- Bergin D, Morrison WB, Carrino JA, Nallamshetty SN, Bartolozzi AR (2004) Anterior cruciate ligament ganglia and mucoid degeneration: coexistence and clinical correlation. *Am J Roentgenol* 182:1283–1287
- Brown MF, Dandy DJ (1990) Intraarticular ganglia of the knee. *Arthroscopy* 6:322–323
- Bui-Mansfield LT, Youngberg RA (1997) Intraarticular ganglia of the knee: prevalence, presentation, etiology, and management. *Am J Roentgenol* 168:123–127
- Caan P (1924) Cyst formation (ganglion) in an anterior cruciate ligament of the knee. *Deutsch Z Chir* 186:403–408
- Choi NH, Kim SJ (2002) A ganglion of the anterior cruciate ligament causing erosion of the lateral femoral condyle: a case report. *J Bone Joint Surg* 84[A]:2274–2276
- Do-Dai DD, Youngberg RA, Lanchbury FD, Pitcher DJ, Garver TH (1996) Intraligamentous ganglion cysts of the anterior cruciate ligament: MR findings with clinical and arthroscopic correlations. *J Comput Assist Tomogr* 20:80–4
- Johnson WL, Corzatt RD (1993) Ganglion cyst of the anterior cruciate ligament: a case report of an unusual cause of mechanical knee symptoms. *Am J Sports Med* 21:893–894
- Kang CN, Kim DW, Kim DJ, Kim SJ (1999) Intraarticular ganglion cysts of the knee. *Arthroscopy* 15:373–378
- Katakuni K, Yoshiya S, Matsui N, Yamamoto T, Kurosaka M (2003) An intraligamentous ganglion cyst of the anterior cruciate ligament after traumatic event. *Arthroscopy* 19:1019–1022
- Krudwig WK, Schulte KK, Heinemann C (2004) Intra-articular ganglion cysts of the knee joint: a report of 85 cases and review of the literature. *Knee Surg Sports Traumatol Arthrosc* 12:123–129
- Lu CY, Hiseh TJ, Huang HT, Wang CK, Liu GC (2002) A case report of an unusual location of pericruciate meniscal cyst with adjacent bony erosion. *Clin Imaging* 26:299–301
- Parish EN, Dixon P, Cross MJ (2005) Ganglion cysts of the anterior cruciate ligament: a series of 15 cases. *Arthroscopy* 21:445–447
- Yasuda K, Majima T (1988) Intra-articular ganglion blocking extension of the knee: brief report. *J Bone Joint Surg* 70[B]:837
- Zantop T, Rusch A, Hassenpflug J, Petersen W (2003) Intra-articular ganglion cysts of the cruciate ligaments: case report and review of the literature. *Arch Orthop Trauma Surg* 123:195–198