

A Carpometacarpal Joint Ganglion Cyst Causing Median Neuropathy

Todd C. Battaglia, MD, MS, Michael E. Pannunzio, MD, and Abhinav B. Chhabra, MD

Ganglion cysts are common wrist masses and may cause median neuropathy. The great majority of volar wrist ganglia arise from the radioscaphoid or scaphotrapezoid joint, with a smaller percentage originating from the pisotriquetral joint.^{1,2} The carpometacarpal joints are uncommon locations for ganglia, especially for cysts causing median nerve compression. A literature review of ganglia within the carpal tunnel syndrome found only two reports of carpometacarpal ganglia causing median neuropathy.^{3,4} We describe carpal tunnel syndrome in a 29-year-old woman that was caused by a ganglion cyst arising from the second carpometacarpal joint.

CASE REPORT

A 29-year-old right-hand-dominant nursing student and waitress presented with a 1-year history of progressive numbness and tingling in her right thumb and index and long fingers without history of trauma. During that month, she had noted a small mass in her palm. Conservative treatment measures including nonsteroidal anti-inflammatory drugs and splinting failed to provide any lasting relief. She reported significant nighttime pain and paresthesias, but review of systems was otherwise negative for fevers, chills, or other systemic symptoms. Her medical history was positive for migraine headaches.

On physical examination, a soft mass measuring approximately 2.0 × 1.0-cm was palpable at the radial distal aspect of the transverse carpal ligament. The overlying skin was normal. Two-point discrimination was 5 to 6 mm in all digits; intrinsic and thenar strength was 5 out of 5 without evidence of thenar atrophy. Radial pulse and digital capillary refill were normal. The findings of provocative maneuvers for cubital tunnel were equivocal, but Phalen's, Tinel's, and carpal tunnel compression maneuvers were strongly positive, causing dysesthesias into the radial 3 digits. Examination of the contralateral extremity yielded unremarkable findings.

Plain radiographs showed no evidence of bony or ligamentous abnormality. Magnetic resonance images demonstrated a 3.5 × 1.0 × 1.0-cm homogenous mass

with low T₁ signal, increased signal on T₂-weighted short tau inversion recovery (STIR) images, and no significant enhancement (Figure 1). The collection of fluid appeared to arise at the second carpometacarpal joint and extend into the carpal tunnel, situated between the flexor pollicis longus and flexor digitorum tendons. The mass was dorsal (deep) to the median nerve, displacing and deforming the nerve within the carpal tunnel.

A presumptive diagnosis of ganglion cyst was made, and excisional biopsy was performed.

DISCUSSION

Ganglion cysts are an infrequent but well-recognized cause of carpal tunnel syndrome. Although median neuropathy at the carpal tunnel is much more commonly a result of physiologic processes (eg, nonspecific tenosynovitis, diabetic or alcoholic neuropathy, or alterations in fluid balance), any anatomic process that decreases the size of the canal or increases the content of the canal may cause carpal tunnel syndrome. Included in the latter are numerous local "tumors" such as hypertrophic synovium, lipoma, neuroma, giant cell tumors of tendon sheath (aka, xanthomas or nodular tenosynovitis), soft-tissue sarcomas, and ganglion cysts, which are the most common mass implicated in carpal tunnel syndrome.^{1,4-8}

Ganglion cysts are the most common hand and wrist tumor overall; 60% of all tumors in these locations are gan-

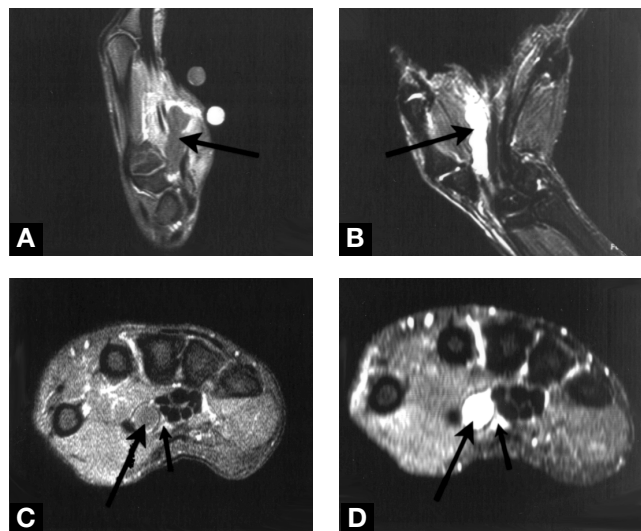


Figure 1. Magnetic resonance images. (A) T₁-Weighted sagittal (postcontrast) and (B) T₂-weighted short tau inversion recovery (STIR) coronal images demonstrating large homogenous carpal mass. (C) T₁-Weighted and (D) T₂-weighted STIR axial images demonstrating carpal mass (large arrows) compressing median nerve (small arrows).

Dr. Battaglia was Chief Resident, Department of Orthopaedic Surgery, University of Virginia Health Sciences Center, Charlottesville, Virginia, when this article was written. He is now Sports Fellow, Department of Orthopaedic Surgery, New England Baptist Hospital, Boston, Massachusetts. [AU: OKAY TO KEEP FORMER TITLE AS RESIDENT IN ADDITION TO CURRENT TITLE? WILL PREVENT QUESTIONS LATER ABOUT PAPER'S ELIGIBILITY FOR THE RWA COMPETITION.]

Drs. Pannunzio and Chhabra are Assistant Professors, Department of

gion cysts. Women are 2 to 3 more times more commonly affected than are men. Ganglia may occur at all ages but are less common in children. The etiology is unclear but is thought to involve mucinous degeneration within the dense fibrous tissue of a joint capsule or tendon sheath, producing an outpouching containing synovial-like fluid.^{1,2,9} Hence, ganglia are usually located adjacent to tendons and joints—see the Box.

Diagnosis

Although ganglia may also form in an intraosseous location (in which case they appear on plain films as well-defined radiolucent areas with a sclerotic border), most are purely soft-tissue masses; thus, the findings on plain radiographs are usually unremarkable. Magnetic resonance imaging is the most helpful radiographic tool, demonstrating a cystic, homogenous structure of low signal on T₁-weighted images and high intensity on T₂-weighted images. Ganglion cysts do not enhance with gadolinium.

Clinical and radiographic differentiation of ganglion cysts from other common soft-tissue tumors of the hand is critical, but usually straightforward:

- Ganglia are often painful and frequently fluctuate in size as a result of periodic accumulation and regress of fluid within the cysts.
- Lipomas and other solid tumors are firmer, and they slowly but progressively enlarge until treated.^{2,9}
- Although malignancy may be painful, benign soft-tissue tumors are usually relatively painless.
- Ganglia also transilluminate on clinical examination, thus differentiating them from solid soft-tissue tumors.
- The magnetic resonance imaging appearance of these solid lesions reflects their fatty or connective-tissue

“Ganglion cysts are the most common hand and wrist tumor overall; 60% of all tumors in these locations are ganglion cysts.”

matrix, rather than the fluid-filled cavity of a ganglion, which results in greater signal intensity on T₁-weighted images.

- Furthermore, tumors of nerve or tendon sheath origin demonstrate continuity with the structure of origin.

Pathologic evaluation of ganglion cysts:

- Analysis demonstrates an outer wall composed of randomly oriented collagen layers, with few fibroblasts or other cells.
- Ganglion cysts have no synovial or epithelial lining, rendering the term cyst a misnomer.
- Ganglia are frequently multilobulated and are filled

Common Locations For Hand and Wrist Ganglia.

The dorsal wrist is the most common location (60% to 70% of all hand and wrist ganglia), but the volar-radial wrist (13% to 20%), dorsal distal interphalangeal joint (aka, mucous cyst), and volar proximal digital flexion crease (aka, flexor retinacular cyst) are also common locations. Of volar wrist ganglia, more than 90% arise from the radioscaphoid or scaphotrapezium joint, with most of the remainder stemming from the pisotriquetrum joint.^{1,2} The carpometacarpal joints are uncommon locations for ganglia; a literature review of ganglia within the carpal tunnel found only 2 reports of carpometacarpal ganglia causing median nerve symptoms.^{3,4}

with clear, mucinous fluid containing glucosamine, albumin, and high concentrations of hyaluronic acid.^{1,2}

Management Options

Ganglia are benign lesions and cause only local symptoms. Malignant transformation has never been reported. Treatment options include observation, cyst puncture and aspiration with or without injection of steroid, or surgical excision. The traditional traumatic closed rupture with a sharp blow (“the Bible treatment”) is associated with a high recurrence rate, often estimated at more than 50%. Puncture with aspiration is more successful, with reported cure rates of up to 85% with multiple aspirations.^{1,2} For volar wrist ganglia, however, cyst puncture with aspiration is often avoided because of the risk of injury to the radial artery or median nerve branches.² In these cases, cyst excision is frequently recommended. Surgical excision may also be indicated for pain, interference with activity, or neuropathy. If removal is indicated, it is important to resect the stalk that connects the cyst cavity with the joint or tendon sheath of origin to minimize the likelihood of recurrence. Allen’s test should be used preoperatively to evaluate patients with volar ganglia; an occluded ulnar artery should further emphasize the importance of radial artery preservation.¹

Surgical Removal in this Case

In this case, given the size and location of the lesion and the patient’s unremitting neurologic symptoms, surgical removal was recommended. An extended incision across the wrist crease was required for exposure. The mass was found dorsoradial to the median nerve and extended into the bifurcation between the median nerve proper and its deep motor branch (Figure 2A). The appearance of the mass was consistent with the typical appearance of a ganglion—a pale, shiny surface with soft, gelatinous consistency (Figure 2B). After transection of the stalk, clear, viscous fluid was expressed from the cyst. Pathologic examination of the specimen confirmed the diagnosis of ganglion

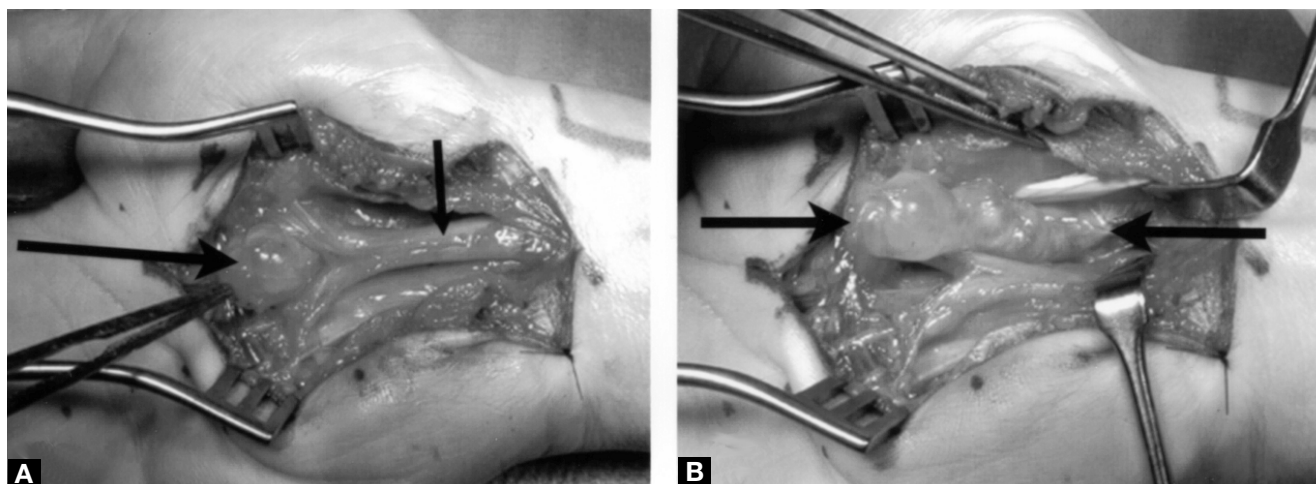


Figure 2. Intraoperative photographs. **(A)** In situ location of mass (large arrow), dorsal-radial to median nerve (small arrow) and extending into nerve bifurcation. **(B)** After complete exposure of the mass (arrows).

cyst. The patient's pain and paresthesias were completely resolved by her first postoperative visit, and she remained symptom free at her most recent follow-up, more than 1 year postoperatively.

AUTHORS' DISCLOSURE STATEMENT

The authors report no actual or potential conflict of interest in relation to this article. [AU: OKAY TO PRINT THIS STATEMENT?]

REFERENCES

1. Angelides AC. Ganglions of the hand and wrist. In: Green D, ed. *Operative Hand Surgery*. 3rd ed. New York: Churchill Livingstone Inc; 1993:2157-2171.
2. Thornburg LE. Ganglions of the hand and wrist. *J Am Acad Orthop Surg*. 1999;7:231-238.
3. Kato H, Ogino T, Nanbu T, Nakamura K. Compression neuropathy of the motor branch of the median nerve caused by palmar ganglion. *J Hand Surg [Am]*. 1991;16:751-752.
4. Kobayashi N, Koshino T, Nakazawa A, Saito T. Neuropathy of motor branch of median or ulnar nerve induced by midpalm ganglion. *J Hand Surg [Am]*. 2001;26:474-477.
5. Brooks DM. Nerve compression by simple ganglia: a review of thirteen collected cases. *J Bone Joint Surg Br*. 1952;34:391-400.
6. Harvey FJ, Bosanquet JS. Carpal tunnel syndrome caused by a simple ganglion. *Hand* 1981;3:164-165.
7. Kerrigan JJ, Bertoni JM, Jaeger SH. Ganglion cysts and carpal tunnel syndrome. *J Hand Surg [Am]*. 1988;13:763-765.
8. Nakamichi K, Tachibana S. Unilateral carpal tunnel syndrome and space occupying lesions. *J Hand Surg [Br]*. 1993;18:478-479.
9. Froimson AI. Benign solid tumors. *Hand Clin*. 1987;3:213-217.